

Effective Treatment of Cutaneous Warts Using a Novel 5-FU/SA Compounded Topical Medication

A compounded formulation of 5-fluorouracil and salicylic acid housed in an adhesive vehicle has demonstrated success in treating cutaneous warts in patients of all ages, including this case report of severe periungual warts. This is the first column in a four-part case series on effective wart treatment.

Steven Leon, MS, PA-C

I do not know of anyone who is thrilled when they see a recalcitrant or extensive case of cutaneous warts. The treatments we currently have simply do not work that well. While data report that salicylic acid (SA) and cryodestruction have wart cure rates of 52% and 49%, respectively,¹ these rates are misleading because the growths can go away on their own. Although data is limited, a recent study showed two-thirds of warts go through spontaneous regression within a 2-year period.² However, many persist longer and are refractory despite a number of tools for treatment. A Cochrane meta-analysis found that SA and cryotherapy were marginally effective at best.³ All other treatments, from intralesional bleomycin to duct tape, were either ineffective or marginally effective or had insufficient high-quality studies to make a determination.³ Further, little data exists to support surgical removal as a treatment option. Experience and anecdotal evidence show that surgical removal is effective, but the majority of patients are

not prime candidates and would likely prefer a nonsurgical or topical approach that is fast and effective.

The only FDA-approved topical medication currently to treat cutaneous warts is 17% SA, which must be applied for months for a chance to get a modest effect. If surgical removal of the wart is not possible, more data-driven professionals may have a detailed conversation with a patient discussing the self-limited nature of warts and the limitations of nonsurgical treatment. But most of the time, health care professionals initiate cryotherapy and hope for the best.

Attempts have been made to improve the effectiveness of topical treatment. Compounding pharmacies routinely make SA plasters, and some clinicians advise SA along with imiquimod or 5-fluorouracil (5-FU) under tape occlusion. Verrumal, a combination of 0.5% 5-FU and 10% SA, has been available for the last 30 years in Europe. This combination of 5-FU and SA has been found

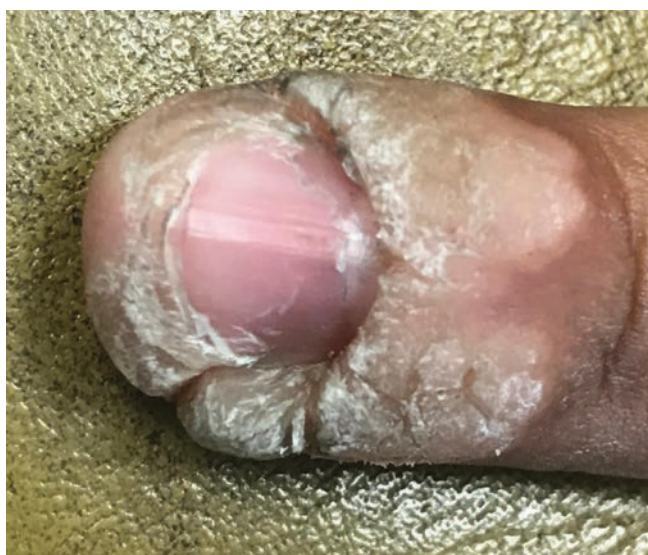

Figure 1. The patient presented with an extensive periungual wart on the left fifth finger.

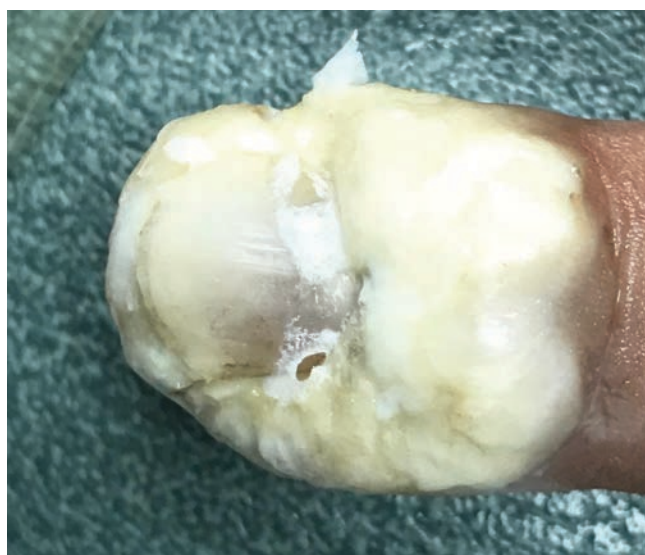


Figure 2. Left fifth finger following 5 days of treatment with WP.

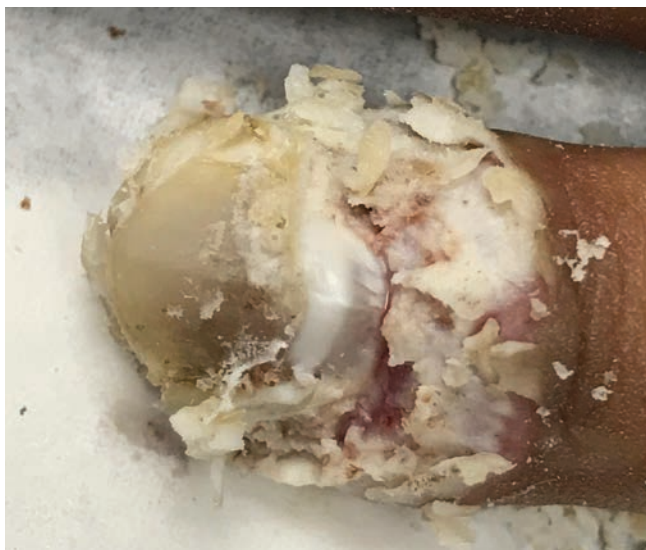

Figure 3. Left fifth finger following curettage due to thick maceration of the skin.

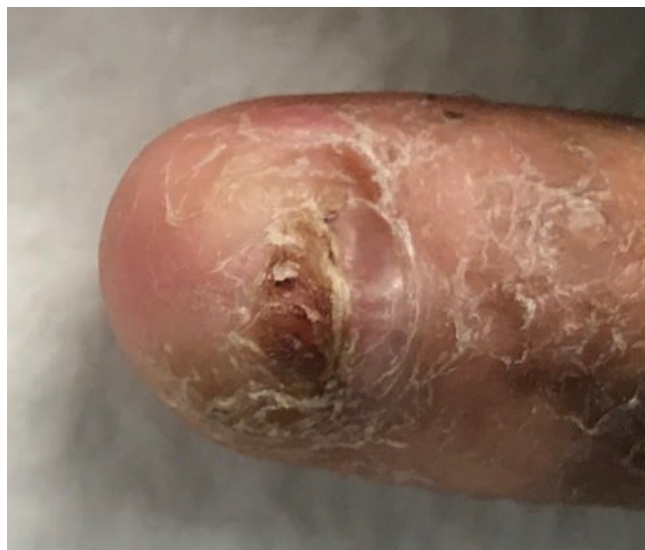

Figure 4. Left fifth finger 1 week after curettage and discontinuation of WP treatment.

to be superior to 5-FU alone for the treatment of common and plantar warts.⁴ Across all studies, complete healing was achieved in 63.4% of common warts treated with 5-FU/SA compared with only 23.1% treated with 5-FU alone. Similar disparity in complete healing was seen in plantar warts (63% vs 11%, respectively). However, these cure rates⁴ were achieved over a 1 to 3 months and not a few weeks as patients desire.

As we well know in dermatology, even the best topical medication is useless unless it can penetrate the skin and reach its desired target, hopefully without adversely affecting normal tissue. In a rapidly growing, hyperkeratotic cutaneous wart, this is a significant challenge. Occlusion can increase the potency of topicals, but if they migrate off the skin (as they inevitably do in the standard solution, gel or cream), they can then cause excessive irritation, which often leads to treatment failure. Furthermore, pulse dosing to allow the irritation to subside does not work well for warts due to their rapid regrowth rate.

Dermatology, perhaps more than any other specialty, knows the benefits that compounded medications can provide for individualizing treatments, and creating novel formulas to solve tough problems.

Wartpeel (WP), a 5-FU (2%) and SA (17%) compounded medication, was patented in 2010. Its development began in 1991 as a collaboration between a pharmacist and a podiatrist to treat plantar warts. The treatment uses a sustained-release topical adhesive gel that releases SA onto the wart to break down keratinocytes and subsequently allow better penetration of 5-FU to the living wart.⁵

At the time I discovered this product, I was working in a low-income area with a high pediatric population and saw between three to five patients with warts per day, much of which recalcitrant. With the exception of surgical removal, all other treatments my colleagues and I tried (cryotherapy, *Candida* antigen, cantharidin,

among others) were only marginally effective; so, I began to experiment with WP. After treating hundreds of patients, I have observed a cure rate of 95% in 1 to 2 weeks (unpublished data), which far exceeds in any nonsurgical method in speed and effectiveness. Additionally, the recurrence rate is low and patient satisfaction is high due to excellent tolerability, even in children, and the fast treatment time. For all these reasons, WP has become a valuable first-line therapy and, in many cases, indispensable.

As we well know in dermatology, even the best topical medication is useless unless it can penetrate the skin and reach its desired target, hopefully without adversely affecting normal tissue.

The information and photos contained in this article (and subsequent articles in this series) will accelerate your mastery of WP and allow you to manage even the most extensive and recalcitrant cutaneous wart cases. This article will highlight the properties of WP, show how it worked in a severe, recalcitrant case of periungual warts, and discuss key patient education points.

About the Treatment

WP is applied by the patient at home and oftentimes is successfully completed with no follow-up visit if the case is not extensive, if treatment days are not routinely skipped, and if the patient stops at the appropriate time (ie, not too early). For most patients, one to two follow-up visits help ensure a high success rate. Good patient education is essential, especially for extensive and widespread cases.

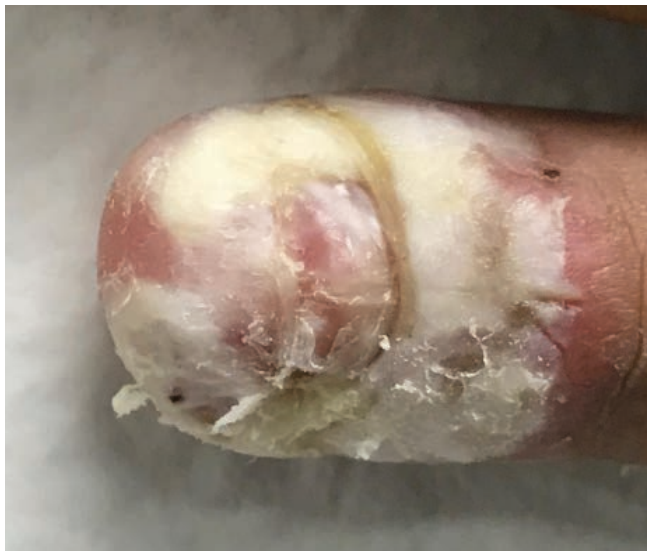

Figure 5. Left fifth finger after 5 days of additional treatment with WP to treat residual wart.

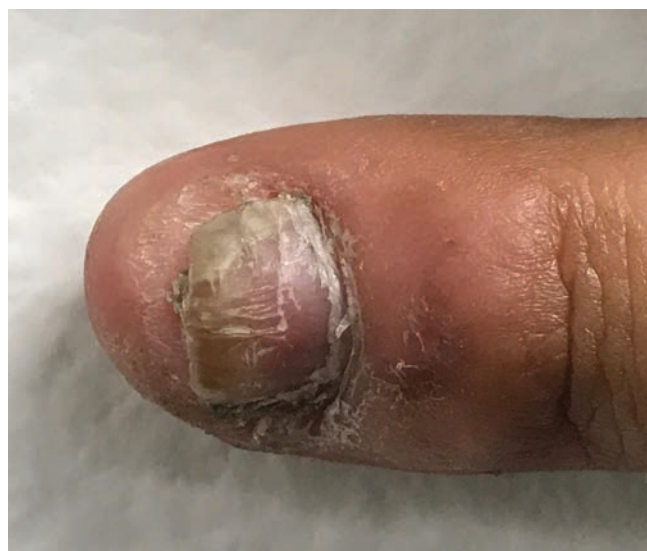

Figure 6. Left fifth finger 4 weeks post treatment. The patient's warts completely resolved.

It is important to understand that the WP vehicle (Remedium delivery system) is just as crucial to the effectiveness of the treatment as the active ingredients. A waterproof tape also comes with the treatment to improve maceration and penetration in hyperkeratotic warts. How WP works is best understood by examining its unique properties.

Selectivity. WP is selective in two ways. First, its fast-drying adhesive gel stays on the wart if allowed to fully dry (approximately 10–15 minutes) and has minimal contact with normal skin. Second, on the microlevel, as an antineoplastic antimetabolite, 5-FU prevents cell replication and proliferation, thereby destroying rapidly growing wart cells faster than healthy cells.^{6,7}

Occlusion and sustained release. Both occlusion and sustained release amplify the effects of topical medication. The sustained-release adhesive gel of WP contains both of these properties. When combined with the waterproof tape, maceration is increased, therefore further enhancing the penetration of the treatment (note: this is only recommended for hyperkeratotic warts on thick skinned areas).

Adhesive vehicle. The patented delivery system is a hybrid of a gel and a glue. It fully dries in 10 to 15 minutes, yet still releases the medication over a period (ie, overnight). The adhesive vehicle also does not dry so hard that it is difficult to remove. With the 5-FU/SA firmly adherent to the wart through the adhesive vehicle, the irritation, erosion, and inflammation so commonly seen with other topical wart medications is minimized.

Synergy. In order to be successful, a wart treatment must penetrate and destroy the hyperkeratotic layers of the wart and prevent recurrence of this fast-growing lesion. All of the above factors work synergistically to overcome a wart's defensive barriers to eliminate the lesion while doing minimal damage to normal, perilesional skin.

Case Report

A 32-year-old man presented with extensive periungual warts on multiple bilateral fingers. The growths were most severe on his left fifth finger, where the patient complained his nail was becoming loose (**Figure 1**). Occupationally, he was a truck driver and wore gloves most of the day with intermittent heavy lifting. He also reported having moderately sweaty palms. Previously, the warts failed to respond to over-the-counter wart remover and multiple sessions of cryotherapy administered by his primary care provider. The patient reported moderate pain in several warts as well as embarrassment and social stigmatization.

The patient was instructed to apply WP at night, allowing it to fully dry, followed by washing it off in the morning. Due to the thickness of the wart, the patient was advised to apply the waterproof tape at night after the WP dried as well as during the day after WP was washed off. He was advised to return in 5 days.

Six days later, the patient returned stating he had used the WP every night and used the tape night and day (**Figure 2**). He stated he was able to work without pain and experienced no discomfort.

Due to the development of thick macerated skin, curettage was performed on day 6 of treatment (**Figure 3**). It was unclear at the end of curettage whether any wart remained. The patient was advised to discontinue WP but continue to wear the tape at night to aid in debridement, and he was to return for follow up in 1 week. At that follow-up, the patient reported that the remaining macerated tissue had either fallen off or was about to fall off and he picked it off with his fingers or a tweezer. Closer inspection revealed residual wart (**Figure 4**), and the patient was advised to repeat WP treatment for 5 days with tape in the evening only.

When the patient returned another 6 days later (day 18 of treatment), he complained of minor tenderness and stinging when he applied WP (**Figure 5**). This is usually a sign that the

General How-to for Patients

1. Let it dry. I explain to patients that “It’s not a cream or a gel, it’s a glue so you need to let it fully dry.” WP dries completely within 10 to 15 minutes. This can be accelerated with a fan or hair dryer on the coolest setting. The medication should be firm to the touch; this can be tested with a cotton swab or the plastic spatula included in the treatment kit. It is important to note that the tape should not be applied until the medication is fully dried so as to not spread the application onto normal skin. Spreading the medication onto normal skin can cause irritation and possible early discontinuation.

2. Avoid skipping days. This is the most common reason for treatment failure. Warts grow quickly and need to be completely destroyed so they do not recur. So, I always tell patients not to skip days and discuss how skipped applications can lead to treatment failure. I explain that if a patient does skip an application at night, the patient should put it on in the morning. If a patient completely misses one day, then 2 days should be added to the recommended treatment time.

3. Apply to the top and sides of the wart. Most often, patients focus their application to the top of the wart. This may be appropriate for flatter warts, but any warts with height or hyperkeratosis should receive an application of WP on its sides as well. Think of WP as frosting; instead of only putting a small bit on the top as with cupcakes, the wart should be fully covered as with a sheet cake. I also tell patients if they are having a hard time getting it exactly on the wart, it is better to go a little farther onto normal skin than to put too little on.

4. Note the color, not the size. Patients are often disappointed that their wart is the same size during a follow-up appointment. However, patients are not often paying attention to the white color, a sign that the medication is working. Flat warts and genital warts will form a crust and flatten out. With these warts, patients often think that the postinflammatory hyperpigmentation indicates the wart is still present. Patients were often surprised when we performed curettage and most of the white desiccated wart was removed.

5. Discontinue use if you experience irritation. Irritation and erythema are caused by a number of reasons, including:

- The medication did not fully dry before tape was applied, and WP irritated perilesional skin;
- User error on application, causing the medication to be applied repeatedly to perilesional skin directly;
- Initial sensitivity to WP, such as in a few patients younger than 10 years who respond much faster, often in less than 5 days, but experience more burning and erythema than other patient; or
- After sustained use, WP eliminated the wart and is being applied to healthy skin.

Patients, who want to see results as soon as possible, can be overzealous and continue to apply WP even as their skin becomes severely irritated. If the wart was flat and irritation is starting to occur, then it is likely the wart has resolved and treatment should be discontinued to allow normal skin to grow in the area.

6. Treatment length varies by wart presentation. Length of treatment can vary widely depending on a number of characteristics of the wart. A filiform wart may only require 2 to 4 days of treatment, but a thick plantar wart may need several weeks of nightly application and occlusion.

Read tips for use, application, and more of this novel 5-FU/SA compounded medication online from *The Dermatologist*.



wart has been destroyed and the treatment is contacting normal skin. Light curettage was performed, and normal pink dermis was visualized. The patient was advised to discontinue all treatment and return in 4 weeks.

At follow-up 4 weeks posttreatment, the wart was found to be fully resolved. It required an active treatment time of only 11 days. The other warts, which were less severe, were also treated with the WP treatment and had fully resolved. The patient was very pleased with the results (Figure 6) and relieved that his 2-year battle with warts was over.

This case study illustrates how even the most severe warts can be treated quickly and with little discomfort or disruption to patients' lives with WP.

Safety

The two ingredients, 5-FU and SA, are commonly used as separate treatments in dermatology practices, so their side effects are well documented. With WP, there is no specific safety data for the product despite what we know about 5-FU and SA individually from the literature. For patients, proper education on treatment use and appropriate follow up is critical to the success of their case and safety of the treatment.

In my practice, a few patients have experienced early discontinuation due to pain, burning, and/or erythema. The patients that did discontinue treatment early were patients who did not let WP fully dry, especially on application to flat warts in sensitive, thin-skinned areas, or who were aged 6 years or younger. For similar patient groups, I recommend treating only one small area initially so the patient can gain experience before expanding the treatment.

It is difficult for patients to scar with WP. It is strong and fast acting, but it is not so powerful that it can easily damage the dermis. When WP irritates the dermis, burning, stinging, and pain occur at the application site, and the vast majority of patients discontinue use because of the discomfort. In my experience, one case of scarring did occur. This patient had a high pain tolerance and was applying WP on the distal second toe. He did not let the treatment dry or apply the tape following application. It routinely transferred to his great toe and caused scarring, which he hardly noticed due to his high pain

tolerance. Hyperpigmentation does routinely occur but is less than with cantharidin, cryotherapy, and hyfrecation.

Discussing WP With Your Patient

Because patients most often have to pay cash for this medication, every provider will have to decide how to introduce this product to their patients. I have worked in a predominantly Medicaid population, and unless desperate, most patients want to try covered procedures (eg, cryotherapy) first, even after I explained their poor efficacy. If the wart has not improved by the next appointment, many patients will then begin to consider WP as a therapeutic option. I have also worked in middle-class areas where 75% of patients will want WP at the first visit when informed about its contrasts with existing nonsurgical treatments. Additionally, patients are used to going to their own pharmacy, so the prescribing health care professional will have to explain that this is a patented medicine that only comes through the mail from one specific pharmacy.

As with any therapy, there were few treatment failures among the patients who received WP in my practice. Some patients were immunosuppressed patients; some had severe and widespread palmoplantar warts; and a few patients, several of whom were children younger than 6 years, had excessive irritation or complained of burning or pain.

Conclusion

I always present WP as an option for wart removal, even if patients must pay out of pocket to receive the treatment. Its effectiveness, as demonstrated in the mentioned case report, is invaluable in eliminating warts that can cause pain, embarrassment, and social stigma. Many patients with warts present on their first visit having already had multiple treatments and are looking for new, more effective options. Due to its speed, effectiveness, and tolerability, WP has become a vital first-line treatment for cutaneous warts. ■

Mr Leon is a dermatology physician assistant in Simi Valley, CA.

Disclosure: The author reports no relevant financial relationships.

References

1. Kwok CS, Holland R, Gibbs S. Efficacy of topical treatments for cutaneous warts: a meta-analysis and pooled analysis of randomized controlled trials. *Br J Dermatol*. 2011;165(2):233-246. doi:10.1111/j.1365-2133.2011.10218.x
2. Loo SKF, Tang WYM. Warts (nongenital). *Am Fam Physician*. 2010;81(8):1008-1009.
3. Kwok CS, Gibbs S, Bennett C, Holland R, Abbott R. Topical treatments for cutaneous warts. *Cochrane Database Syst Rev*. 2012;(9):CD001781. doi:10.1002/14651858.CD001781.pub3
4. Zschocke I, Hartmann A, Schlöbe A, Cumberow R, Augustin M. Efficacy and benefit of a 5-FU/salicylic acid preparation in the therapy of common and plantar warts—systematic literature review and meta-analysis [in German]. *J Dtsch Dermatol Ges*. 2004;2(3):187-193. doi:10.1046/j.1439-0353.2004.04703.x
5. Herman C, inventor; MedCara LLC, assignee. Composition and method for treatment of warts. US patent 7,655,668 B1. February 2, 2010.
6. Gladsjo JA, Alió Sáenz AB, Bergman J, Kricorian G, Cunningham BB. 5% 5-fluorouracil cream for treatment of verruca vulgaris in children. *Pediatr Dermatol*. 2009;26(3):279-285. doi:10.1111/j.1525-1470.2008.00800.x
7. Salk RS, Grogan KA, Chang TJ. Topical 5% 5-fluorouracil cream in the treatment of plantar warts: a prospective, randomized, and controlled clinical study. *J Drugs Dermatol*. 2006;5(5):418-484.